

Waldenstrom and dermatology

Kate Mimken, RN, BSN, FNP

October 28, 2021



CONFIDENTIAL – Contains proprietary information.
Not intended for external distribution.

1

Objectives

- To understand disease related cutaneous manifestations of Waldenstrom's
- To understand treatment related cutaneous manifestations of Waldenstrom's
- To understand what to do with either disease or treatment related skin effects

2 | Kate Mimken, FNP

CONFIDENTIAL – Contains proprietary information.
Not intended for external distribution.



2

Quick overview of WM

- The IgM protein is the protein which is overproduced in WM
 - We test this through labs called quantitative immunoglobulins and the M-spike
- IgM is a large molecule and can infiltrate many things including the skin
- Because of the size of the molecule it can also cause other complications which can lead to skin disorders which we will discuss in further detail
- There are 3 classifications of WM (IgM MGUS, smoldering, and symptomatic)
- Various treatments that are necessary to treat *symptomatic WM* can also lead to skin/hair/nail changes

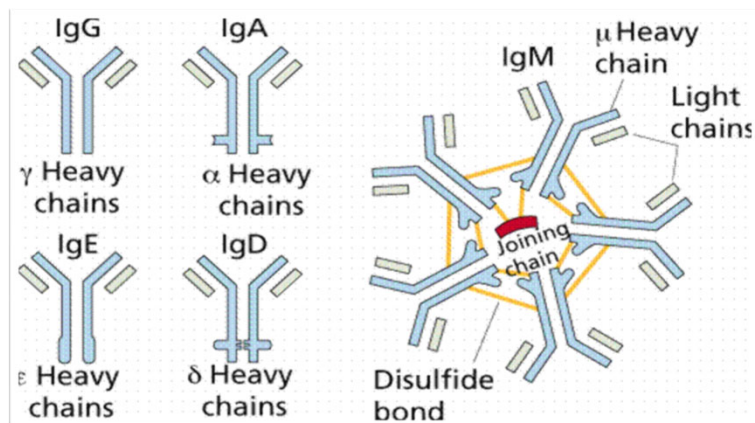
3 | Kate Mimken, FNP

CONFIDENTIAL – Contains proprietary information.
Not intended for external distribution.



3

IgM molecule compared to others



4 | Kate Mimken, FNP

CONFIDENTIAL – Contains proprietary information.
Not intended for external distribution.



4

IgM levels

- The level of IgM and/or the percentage of LPL (WM) cells in the bone marrow varies tremendously between WM patients
- Some patients with very low IgM levels have lots of symptoms while others with very high levels may not have symptoms at all!

5

Various Dermatologic Conditions

Treatment Related

- Brittle/cracking nails
- Corkscrew hair changes
- Skin infections
- Bruising/bleeding
- Psoriasis post Rituxan
- Neutrophilic dermatosis (Sweets syndrome) and neutrophilic eccrine hidradenitis

Disease Related (~5% patients w/ WM)

- LPL cell infiltration
- Hyperviscosity
- Purpura
- Raynaud's phenomenon
- Livedo reticularis
- Vasculitis
- Chronic urticarial (Schnitzler's syndrome)

6

Disease Related

- Dermatologic manifestations with WM are a less common presenting symptom upon diagnosis with only about 5% of people having this.
- There is neoplastic causes meaning the skin is infiltrated with the LPL cells and non-neoplastic meaning it is caused from complications of the IgM paraprotein. We will discuss these in the upcoming slides.

7 | Kate Mimken, FNP

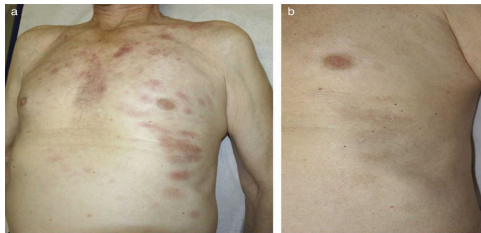
CONFIDENTIAL – Contains proprietary information.
Not intended for external distribution.



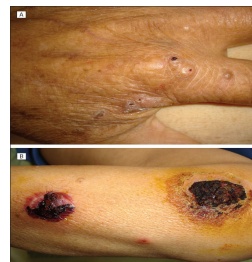7

Disease Related (cont)

- Rarely the lymphoplasmacytic cells can infiltrate the tissue
- The rash can range from reddish-brown to purple w/ plaque like texture
- When IgM infiltrates the skin it is called cutaneous macroglobulinosis or bullous disease



Actas Dermosifiliogr. 2018;109:75-8



Gressier L, Hotz C, Lelièvre J, et al

8 | Kate Mimken, FNP

CONFIDENTIAL – Contains proprietary information.
Not intended for external distribution.



8

Hyperviscosity

- Hyperviscosity with WM is common and can cause complication (bleeding, edema, headaches)
- This is when the blood becomes thick/sludge like from excess proteins in the blood
- Because of bleeding risk use caution with brushing/flossing, blowing your nose
- The thicker blood can cause swelling in the legs (edema) which can cause the skin to blister or weep

9 | Kate Mimken, FNP

CONFIDENTIAL – Contains proprietary information.
Not intended for external distribution.



9

Disease Related (cont)

Cryoglobulinemia causes some of the dermatologic conditions associated w/ WM

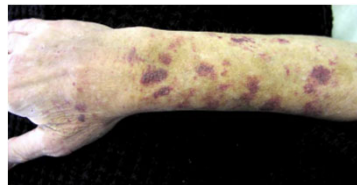
This is when blood proteins clump/precipitate in cold temps

Tested through a blood sample

Purpura- dark purple bruised looking spots on extremities

- This can cause pain at time is associated with vessel occlusion
- Can also be a result of hyperviscosity

Lehman, J. 2010



10 |

CONFIDENTIAL – Contains proprietary information.
Not intended for external distribution.

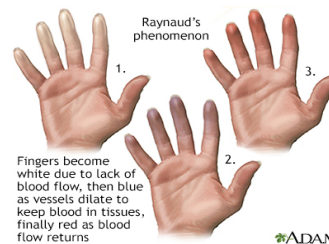


10

Disease Related (cont)

Raynaud's phenomenon-

- occurs in cold temps from lack of blood flow
- Can cause acrocyanosis which is a blueish discoloration of the extremities, ears, and tip of nose
- Raynaud's occurs in cool or cold temperatures. This is when fingers become white, blue/purple from lack of blood flow, when blood flow return they become red.
- Keeping hands and/or feet warm with gloves, socks, hand or feet warmers to decrease pain and symptoms associated with Raynaud's



11 | Kate Mimken, FNP



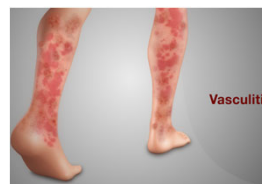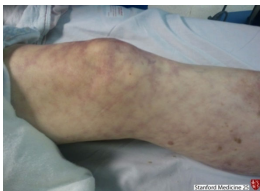11

Disease Related (cont)

Cryoglobulinemia related conditions:

Livedo reticularis this web-like rash can be benign and transient or pathologic/more consistent or permanent

Vasculitis inflammation/narrowing or blockage of blood vessels



12 | Kate Mimken, FNP

CONFIDENTIAL – Contains proprietary information.
Not intended for external distribution.



12

Schnitzler Syndrome

- Urticarial eruptions- neutrophil (WBC) infiltrates
- Associated with IgM protein- more common with IgM Kappa vs IgM lambda
- Often have constellation of other symptoms (fever, bone or joint pain, swollen lymph nodes, and neuropathy)
- Rare and underdiagnosed
- Treatment is directed at treating WM and a medication called anakinra (immunosuppressant to target interleukin 1)
- Tania Jain, Chetan P. Offord, Robert A. Kyle, David Dingli. (2013)

13 | Kate Mimken FNP

CONFIDENTIAL – Contains proprietary information.
Not intended for external distribution.



13

Neutrophilic dermatosis

- This is also called Sweets syndrome, named after Robert Douglas Sweet
- It is characterized by clinical, pathological, and lab findings
 - Clinical findings are fever, tender/red skin lesions, sometimes can affect areas outside the skin
 - Labs show increased neutrophils (a portion of the white blood cell)
 - Biopsy (pathology) of the lesions shows infiltration of mature neutrophils in the upper layer of the dermis
- Some people can have this without have a cancer diagnosis, but often times it is from an underlying malignancy
- Treatment requires systemic corticosteroids and sometimes topical steroid or injection into the skin lesion

• Al-Musalhi, B., Gerstein, W. (2016)

14 | Kate Mimken, FNP

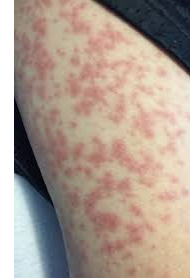CONFIDENTIAL – Contains proprietary information.
Not intended for external distribution.



14

Neutrophilic eccrine hidradenitis

- This is a type of neutrophilic dermatosis
- This is a rash/skin eruption that is associated with chemotherapy most of the time
 - When chemotherapy stops, the rash generally improves.
- It affects the eccrine (sweat glands) that make up most of the body
- Can appear infectious and some people have accompanying fevers.
- Definitively diagnosed by skin biopsy
- It is self limiting, but can be treated with steroids (cautiously)



Crane JS, Krishnamurthy K. 2021

Mills, L. DO, Steinmetz-Rodriguez, C. DO, Folkes, A. DO, Shecter, R. DO, FAOCD

15 |

CONFIDENTIAL – Contains proprietary information.
Not intended for external distribution.



15

Changes to skin when WM is managed

- There can be changes to skin when WM is managed, these are mostly related to treatment side effects.
- Usually when specifically related to WM, meaning the skin lesion are infiltrated with IgM protein, they usually improve with treatment and can flare when disease progresses
- You want to have a biopsy to determine the exact cause, because it could be related to other skin conditions or amyloidosis (another plasma cell disorder)

16 | Kate Mimken, FNP

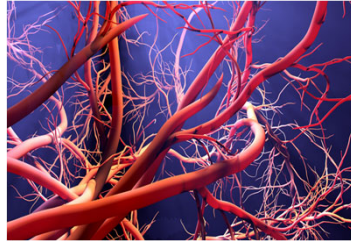CONFIDENTIAL – Contains proprietary information.
Not intended for external distribution.



16

Epidermal Growth Factor Receptor (EGFR)

- Epidermal growth factor is responsible for development/growth of new blood vessels
- Ibrutinib is intended to block BTK, but can also block the EGF receptor which can lead to unintended side effects
 - Rash
 - Bleeding/bruising
 - Infections (skin as well as systemic)
 - Atrial fibrillation
 - High blood pressure (hypertension)



17 |

CONFIDENTIAL – Contains proprietary information.
Not intended for external distribution.



17

Skin Infections

- Staphylococcus aureus- can be minor to very serious, requires oral antibiotics
 - Often times redness, pain, swelling of the skin, fevers
 - Called “cellulitis”
- Folliculitis- most minor type of staph infection at the base of a hair follicle, does not always require treatment, but can require an topical (applied to skin) antibiotic
- Panniculitis- inflammation of subcutaneous fat (adipose) tissue
 - May require corticosteroids and/or lower dose of ibrutinib

Sibaud, V., Beylot-Barry, M., Protin, C., Vigaros, E., Recher, C., & Ysebaert, L. (2020).

Fabbro SK, Smith SM, Dubovsky JA, Gru AA, Jones JA.

18 | Kate Mimken FNP

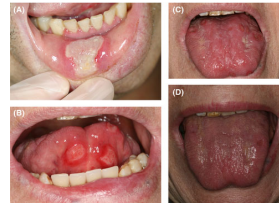CONFIDENTIAL – Contains proprietary information.
Not intended for external distribution.



18

Skin Infections (cont)

- Herpes simplex and zoster (Shingles)
 - Prevention with medication or Shingrix vaccine
 - Post herpetic neuralgia can occur
- Aphthous ulcers/stomatitis
 - Generally not infectious or assoc. w/ neutropenia
 - Treat with corticosteroids (systemic and topical)
 - Pause ibrutinib and dose reduce



19 | Kate Mimken FNP

CONFIDENTIAL – Contains proprietary information.
Not intended for external distribution.



19

Skin changes and what to do?

- Most common in the first year of treatment, but can occur at any time
- Cracked skin around fingers/toes, very brittle nails- Keep well moisturized
 - Mane and Tail lotion, Working hands lotion, don't use fragrance/alcohol based products
 - topical solutions such as hydrosoluble nail lacquer (Genadur) and polyureaurethane (Nuvail).
 - Biotin (2.5mg) -caution w/ thyroid
 - Keep clean to prevent infections
- Rash
- Hair changes- some thinning and corkscrew like texture

Bitar, C., Farooqui, M. Z., Valdez, J., Saba, N. S., Soto, S., Bray, A., Marti, G., Wiestner, A., & Cowen, E. W. (2016). Hair and Nail Changes During Long-term Therapy With Ibrutinib for Chronic Lymphocytic Leukemia. *JAMA dermatology*, 152(6), 698–701.
<https://doi.org/10.1001/jamadermatol.2016.0225>

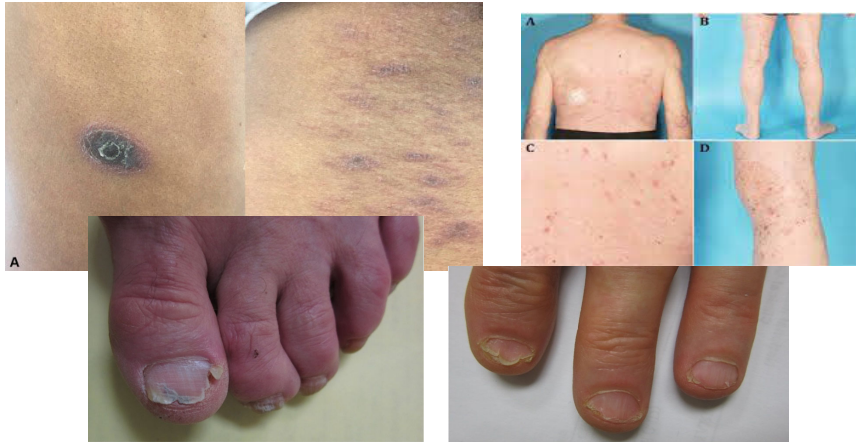20 | Kate Mimken FNP

CONFIDENTIAL – Contains proprietary information.
Not intended for external distribution.



20

Skin/Nail changes



21 | Kate Mimken, FNP

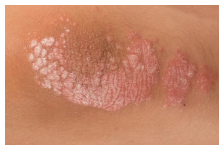CONFIDENTIAL – Contains proprietary information.
Not intended for external distribution.



21

Skin changes (cont)

- Psoriasis post Rituxan-
 - Rare cases (1.04 in 1,000)- reported anytime during treatment
 - Generally resolves once Rituxan stops, sometimes requiring topical or systemic steroids
 - Cause is unknown, but could be from depletion of B-cell causing activation of T-cells, maybe from impaired response to infection, or from Rituxan induced auto-immune changes



- Alahmari, H.S., Alhowaish, N.Y., Omair, M.A. (2019)

22 | Kate Mimken FNP

CONFIDENTIAL – Contains proprietary information.
Not intended for external distribution.



22

Managing Toxicities

- Always discuss with your provider
- There are many interventions as we mentioned above and sometimes they require treatment breaks or dose reductions to minimize side effects

23 | Kate Mimken FNP

CONFIDENTIAL – Contains proprietary information.
Not intended for external distribution.



23

Thank You

Kate Mimken, RN, BSN, FNP



CONFIDENTIAL – Contains proprietary information.
Not intended for external distribution.

24

References

- Alahmari, H.S., Alhowaish, N.Y., Omair, M.A. "Rituximab-Induced Psoriasis in a Patient with Granulomatosis with Polyangiitis Treated with Adalimumab", *Case Reports in Rheumatology*, vol. 2019, Article ID 5450863, 3 pages, 2019. <https://doi.org/10.1155/2019/5450863>
- Alegría-Landa, V, Prieto-Torres, L, Santonja, C, Córdoba, R, Manso, R, Requena, L, Rodríguez-Pinilla, SM. MYD88 L265P mutation in cutaneous involvement by Waldenström macroglobulinemia. *J Cutan Pathol*. 2017;44:625–631. <https://doi.org/10.1111/cup.12944>
- Al-Musalhi, B., & Gerstein, W. (2016). Monoclonal Gammopathy of Undetermined Significance and Neutrophilic Dermatitis. *Oman medical journal*, 31(5), 394–395. <https://doi.org/10.5001/omj.2016.79>
- Bitar, C., Farooqui, M. Z., Valdez, J., Saba, N. S., Soto, S., Bray, A., Marti, G., Wiestner, A., & Cowen, E. W. (2016). Hair and Nail Changes During Long-term Therapy With Ibrutinib for Chronic Lymphocytic Leukemia. *JAMA dermatology*, 152(6), 698–701. <https://doi.org/10.1001/jamadermatol.2016.0225>
- Crane JS, Krishnamurthy K. Neutrophilic Eccrine Hidradenitis. [Updated 2021 Jul 18]. In: StatPearls [Internet]. Treasure Island (FL): StatPearls Publishing; 2021 Jan-. Available from: <https://www.ncbi.nlm.nih.gov/books/NBK448175/>
- Fabbro SK, Smith SM, Dubovsky JA, Gru AA, Jones JA. Panniculitis in Patients Undergoing Treatment With the Bruton Tyrosine Kinase Inhibitor Ibrutinib for Lymphoid Leukemias. *JAMA Oncol*. 2015;1(5):684–686. doi:10.1001/jamaoncol.2015.0457
- Gressier L, Hotz C, Lelièvre J, et al. Cutaneous Macroglobulinosis: A Report of 2 Cases. *Arch Dermatol*. 2010;146(2):165–169. doi:10.1001/archdermatol.2009.359
- Jensen, A. B., Stausbøl-Grøn, B., Riber-Hansen, R., & d'Amore, F. Ibrutinib-Associated Skin Toxicity: A Case of Maculopapular Rash in a 79-Year Old Caucasian Male Patient with Relapsed Waldenström's Macroglobulinemia and Review of the Literature. *Dermatology reports*, 2017, 9(1), 6976. <https://doi.org/10.4081/dr.2017.6976>

25 | Kate Mimken FNP

CONFIDENTIAL – Contains proprietary information.
Not intended for external distribution.

25

References (cont)

- Lehman, J. Waldenström's Macroglobulinemia and the Skin. *IWMF Torch*, 11(1). 2010, 14.
- Mills, L. DO, Steinmetz-Rodríguez, C. DO, Folkes, A. DO, Shecter, R. DO, FAOCD. Neutrophilic Eccrine Hidradenitis: An Unusual Case and a Review of the Literature. Retrieved from: <https://cdn.ymaws.com/www.aocd.org/resource/resmgr/jaocd/contents/volume38/38-10.pdf>. October 10, 2021.
- Oscoz-Jaime S, Agulló-Pérez AD, Llanos-Chavarrí C, Yanguas-Bayona JI. Infiltración cutánea por macroglobulinemia de Waldenström. *Actas Dermosifiliogr*. 2018;109:75–78.
- Seiter, K., Ponce, D. (2021). Waldenström Macroglobulinemia Clinical Manifestations. *Medscape*. Retrieved from <https://emedicine.medscape.com/article/207097-clinical#b3>
- Sibaud, V., Beylot-Barry, M., Protin, C., Vigarios, E., Recher, C., & Ysebaert, L. (2020). Dermatological Toxicities of Bruton's Tyrosine Kinase Inhibitors. *American journal of clinical dermatology*, 21(6), 799–812. <https://doi.org/10.1007/s40257-020-00535-x>
- Tania Jain, Chetan P. Offord, Robert A. Kyle, David Dingli. Schnitzler syndrome: an under-diagnosed clinical entity. *Haematologica* 2013;98(10):1581-1585; <https://doi.org/10.3324/haematol.2013.084830>.
- Vigarios, E., Beylot-Barry, M., Jegou, M-H., Overic, L., Ysebaert, L., Sibaud, V. *British Journal of Haematology*. 2017. 185 (4), 784-788. DOI: <https://doi.org/10.1111/bjh.15620>

26 | Kate Mimken FNP

CONFIDENTIAL – Contains proprietary information.
Not intended for external distribution.

26